

**Intra-arterial chemotherapy for the treatment of colorectal liver
metastases**

–

indications and perspectives

H.Müller

Department of Surgical Oncology
Carl von Hess – Hospital,
Hammelburg,
Germany

Correspondence to:

Herwart Müller MD, FACS
Abt. Onkologische Chirurgie
Carl von Hess – Hospital
D-97762 Hammelburg
Germany
e-mail : H.Mueller@Klinik-Hammelburg.de

Introduction

Colorectal cancer is the second most common malignant disease in developed countries, causing approximately half a million deaths worldwide each year (1). A recent report on mortality from cancer in the European Union between 1955 and 1994 showed that the mortality rates from intestinal cancer is about 15 per 100,000 for women, and 19 per 100,000 for men (2). The liver is the most frequent site of metastases. At the time of diagnosis, 20 % of the patients have synchronous liver metastases (3,4), and 25 – 30 % of patients with initially nondisseminated tumours will develop liver metastases in the following three years (5). Moreover, metastases confined to the liver are frequent, since two thirds of the patients with liver metastases show no evidence of extra-hepatic disease (4). Surgery is the only available curative treatment of colorectal liver metastases, resulting a five-year actuarial survival rate between 25 % and 45 % (6,7). However, curative surgical resection of liver metastases is possible in less than 20 % of all cases with colorectal cancer (7,8). In patients with colorectal liver metastases, hepatic tumour burden, performance status and site of primary tumour are regarded as important prognostic factors (9,10,11).

In the past 40 years, standard first-line chemotherapy regimens have been based on fluoropyrimidines. Treatment with 5-fluorouracil (5-FU), with or without Leucovorin (LV), produces a roughly 20% response rate and a 20% 2-year survival rate (12). Several approaches have been developed to increase the efficacy of fluoropyrimidines, including biomodulation of 5-FU by Leucovorin or Methotrexate or administration of 5-FU by continuous intravenous infusion (13, 14). These strategies only modestly improve response rates without a significant impact on survival (15). During recent years, several new drugs such as oxaliplatin, irinotecan or Raltitrexate have shown great efficacy against colorectal

carcinoma (16-18). The addition of irinotecan and oxaliplatin to 5-FU-based regimens has resulted in superior response rates (40%–50%) as well as longer median survival times (15–17 months). The 2-year survival rate, however, remains poor with 25% to 30% of patients living after 24 months (19-21).

Alternative strategies have been explored to improve the poor outcome of patients with metastatic colorectal cancer. One of these approaches is the intraarterial application of cytostatics via hepatic artery to improve local drug concentrations leading to an increase in response and efficacy. This concept dated back the early 1960s since Sullivan et al. reported the first positive results of continuous intraarterial infusion for liver metastases of gastrointestinal origin (22). In the past three decades, hepatic arterial infusion (HAI) of chemotherapeutics has been used in the treatment of metastatic colorectal cancer with different application forms, cytostatics and regimens. This report focuses on the rationale of HAI, describes technical aspects and analysis data to determine the indication for this approach.

Rationale for Hepatic Artery Infusion

The concept of HAI for treatment of colorectal liver metastases is based on three different principles. First of all, a difference exists in blood supply of benign and malignant tissue in the liver. The liver is perfused by a dual blood supply: the portal venous system and the hepatic arterial circulation. Whereas metastatic cells gain access to the liver through the portal vein, tumour perfusion is via the hepatic arterial system. In contrast, normal hepatic parenchyma receives the bulk of its perfusion through the portal venous system. It has been calculated that the portal vein supplies

approximately 70% to 80% of the blood for normal hepatic tissue perfusion (23,24). Another rationale is the high first pass hepatic extraction of the drug used for this approach. This approach achieves significantly higher concentrations of several cytotoxic agents within the hepatic parenchyma while minimizing systemic toxicity. The observed antitumour effect is relatively great compared to systemic delivery of the same agents (25). The third rationale is the pharmacokinetic principle that most drugs have a steep dose-dependent curve, which means that if drug delivery is increased to tumours, the response rates can be elevated (26,27).

Pharmacological aspects

The ideal agent for regional chemotherapy should have a high local extraction rate, a steep dose – response curve and a rapid total body clearance (27). Throughout the last three decades the fluoropyrimidines 5-FU and fluorodeoxyuridine (FUDR) have been the most commonly used agents in colorectal cancer. Between these agents severe and very interesting discrepancies do exist in terms of metabolism and pharmacology. For FUDR it could be demonstrated that nearly 95% of the drug will be extracted in liver circulation when given via HAI, resulting in a 16-fold higher concentration in hepatic tumours, compared with venous infusion (28).

Pharmacological studies for the mainly used fluoropyrimidine 5-FU have shown a low uptake in the liver combined with a more or less similar systemic exposure compared to systemic drug administration. Kar et al. have shown in an animal model that the systemic exposure for 5-FU is nearly identical for intravenous infusion, intra-arterial administration or intra-arterial stopflow – infusion. Only an isolated perfusion of liver circulation could diminish systemic drug levels (29). Measuring the area-under-the curve (AUC) about 70 – 75 % of the drug is entering the

systemic circulation (30). Despite the low extraction rate for 5-FU inside the liver tumour tissue concentrations are about 10 times higher than plasma concentrations and about two times higher than in normal liver tissue (31). These data explain on a pharmacological basis the small advantage of HAI using 5-FU compared to systemic administration as frontline chemotherapy for colorectal liver metastases (41,50).

Technical aspects of HAI

To perform intra-arterial chemotherapy for the liver intermittent or permanent access to hepatic artery is essential. Since the early 1960s different approaches for cannulation of this vessel have been developed starting from an angiographic approach over angiographic assisted implantation of permanent catheters to surgically implantation of catheters or specific pump systems. Each of these techniques is connected with specific advantages and disadvantages.

The angiographic placement of a catheter into hepatic artery using a Seldinger technique is easy and combined with a small risk to the patient with respect to thrombosis, dissection of arterial wall or bleeding complications. Such a catheter cannot be held in place permanently and should be taken out after at least 48 hours after insertion. Advantage of this approach is the low morbidity, the low risk for thrombosis of hepatic artery even after embolization. A higher incidence for partial or complete thrombosis of hepatic artery has been documented after chemo-embolization of the liver (37) The disadvantage is the inconvenience for the patient to repeat the procedure, if necessary. This technique is typically used for second line treatment after failure of conventional systemic chemotherapeutic regimen when the awaited life time is short and efficacy of such an intervention should be awaited (38,39)

Surgical or angiographic assisted placement of permanent catheters into hepatic artery is always combined with a definite risk for complications like bleeding, thrombosis, infection or migration of the catheter (32). Even after development of complete implantable devices these ports have a high failure rate especially for migration and thrombosis (33). Due to the low flow rate dependent to such port catheters short time or continuous infusion of cytostatics is only possible, but not the application of embolizing substances for chemo-embolization.

The development of totally implantable infusion pumps reduced the rate for complications associated with HAI therapy. Such pump systems are placed in a subcutaneous pocket created at the time of the surgical placement of the hepatic arterial catheter allowing a continuous infusion of cytostatics over 2 to 4 weeks. This continuous infusion decreases the rate of thrombosis, and filling the pump every 2 weeks allows for more convenient ambulatory treatment.(34-36). Continuous infusion for a longer period of time is prerequisite for use of FUDR, the drug with a 95 % uptake and metabolism in the liver. Specific toxicity connected to FUDR continuous application such as chemical hepatitis and sclerosing cholangitis could be diminished by use of dexamethason and dose modification of FUDR (40).

Indications for HAI

A. front line therapy

Since 1979 a series of eleven prospective randomized trials have been published comparing HAI with systemic chemotherapy (table 1).(41-51). One of these trials compared the intra-arterial infusion of 5-FU to a systemic application form (41), another ia. 5-FU plus Leucovorin versus iv. treatment of the same drugs (50), three trials compared regional FUDR

with iv. FUDR and six trials compared HAI of FUDR with either i.v. 5-FU (45,47,48) or i.v.5-FU/LV (46,49,51). Two of these trials compared HAI of FUDR with a control arm of i.v. 5-FU or best supportive care, based on the treating physician's choice (49,51).

All eleven trials showed higher response rates for HAI compared with i.v. chemotherapy ranging from 22 – 62 % for the regional treatment and 9 – 23 % for the systemic arm. In all of these trials over-all survival was longer for the experimental arm (12,7 – 22.7 months) than in the standard arm (7.5 – 19.8 months). While there were trends toward longer times to overall survival times for the HAI arms, these were statistically significant only in the trials from Rougier et al. (FUDR vs. 5-FU or BSC), Allen-Mersh et al. (FUDR vs. 5-FU or BSC) and Kemeny et al. (FUDR vs. 5-FU/ LV). Critical in the trials of Rougier and Allen-Mersh was the fact that systemic chemotherapy with 5-FU or best supportive care (BSC) cannot be accepted as appropriate control arms for metastatic colorectal cancer today.

Two meta-analyses of these seven original trials were conducted, based on the premise that the individual trials were underpowered to detect a survival benefit. Over 600 patients were included. The Meta-Analysis Group in Cancer (52) confirmed the higher response rate seen with HAI (41% versus 14%). Overall, a 27% relative survival advantage was seen in the HAI arms ($p = 0.0009$) compared with the controls. Harmantas et al from Harvard University School in Boston also performed a Meta-analysis for such prospective randomized trials and found that regional infusion chemotherapy with FUDR produced a 10% ($p = 0.041$) and 6% ($p = 0.124$) increased survival at 1 and 2 years, respectively.

Several potential reasons are possible to explain the small benefit in terms of over-all survival despite the superior response rates for HAI. First of all, the study design for some of these trials which allows crossover from one arm to the other will have reduced the definite benefit. Lack of

experience in certain centers leading to greater complication rate in the HAI arm combined with greater toxicity can be another reason. A third explanation for this small survival benefit of HAI treatment is the unexpectedly high rate of extrahepatic disease discovered at laparotomy as well as some technical problems with pump system. Both factors led in some of these trials to a substantial number of patients who had never received regional therapy assigned to HAI arms.

During the last five years new agents have been used in combinations with the fluoropyrimidines for regional chemotherapy of unresectable liver metastases (54-60). One of these drugs is Pirarubicin, a anthracycline analogue, which has given promising data in animal models. Because of higher local tumour concentrations, greater antitumoral effect and lower systemic exposure following intraarterial administration of this drug, Pirarubicin is an excellent candidate for regional chemotherapy (55). The studies from Fallik et al. and Zelek et al. could demonstrate safety, feasibility and efficacy against colorectal tumours with response rates between 39 % and 48 % (56,57).

Kemeny et al. reported one the highest response rates ever published in the treatment of colorectal cancer with 75 % by use of intraarterial FUDR plus Irinotecan (54). Irinotecan is a topoisomerase I inhibitor with proven efficacy in first- and second-line treatment of metastatic CRC. Feasability and safety of this drug for intraarterial use was confirmed by Fiorentini et al., but response rates were in the range of 40 % using Irinotecan as mono therapy (58). Early promising results of intraarterial infusion of Irinotecan in combination with fluoropyrimidines have to be confirmed by larger prospective trials.

This is true also for the use of Oxaliplatin, another new cytotoxic agent with a mechanism of action similar to that of other platinum derivatives, but with a different spectrum of activity (61). Based on positive results in systemic chemotherapy with clinical response rates greater than 50%

when combined with 5-FU/LV this drug has been used for regional chemotherapy in phase I / II trials (59,60). Reported response rates are in the range of 45 – 60 % without unexpected toxicity.

Combination of fluoropyrimidines with one of these new agents seem to improve local response rates, but we have to await further prospective trials about the positive influence of this regional combination therapy on overall survival.

B. inductive therapy

When Bismuth et al. published his paper about neoadjuvant chemotherapy of primarily inoperable colorectal liver metastases in 1996 he defined some new and intriguing rules for oncologic surgery (62). Only about 15 – 20 % of all patients with liver metastases of colorectal origin are candidates for a curative resection. This low rate is dependent to reduced general condition of the patient, metastazation into other organs, a diffuse infiltration of the liver or involvement of vital structures. He could demonstrate that about 15 % of all primarily inoperable liver metastases become resectable after downsizing induced by chemotherapy. The second very interesting fact was that the survival after complete resection after inductive therapy was nearly identical to a curative resection without prior chemotherapy. These data could be confirmed by other groups (63,64). To improve survival data for patients with liver metastases of colorectal origin it seems to be clear that the number of definite resected patients has to be increased. To reach this goal development of specific techniques to reach a maximal shrinkage of liver metastases in a short period of time is needed.

For Oxaliplatin based systemic chemotherapy high local response rates have been reported opening the possibility to operate shrunken liver metastases after inductive chemotherapy. Giacchetti et al published a

prospective trial using FOLFOX regimen with a resection rate of 51 %, but complete resection was possible in only 38 % (65,66). In case of inefficacy of front-line systemic chemotherapy another technique can be used in order to break through tumour cell resistance by high local drug concentrations. Our own group have published data about the efficacy of chemo-embolization as front – and second –line therapy for colorectal liver metastases (67) (graph...). The procedure consists of an intra-arterial chemotherapeutic infusion combined with embolization of the vascular supply to the tumour (68-72).. The combination of the two treatments has theoretical benefits beyond those offered by either treatment given alone. In addition to the ischemic damage caused by the embolization and the cytotoxicity associated with chemotherapy, vascular occlusion results in the prolongation of transit time through the vascular bed of the tumour, with increasing time of exposure of the tumour cells to chemotherapy (70). Furthermore, it has been shown that anoxic damage increases vascular permeability, promoting further infiltration of the chemotherapeutic agent into the tumour. The cytotoxic effect on the vessel wall may result in an irritant vasculitis, causing further occlusion and ischemia (68,70).

In this study melphalan as cytostatic drug and a combination Lipiodol and Gelfoam as embolizing substances to reach a maximal occlusion of the vasculature has been used. (graph 1-4).(67). Despite the low vascularity to tumour formations of colorectal origin a response rate of 43.4 % could be reached. Infiltration of Lipiodol particles into the vascular bed of the tumour will influence the results of the CT scan.

C. second line therapy

For patients refractory to standard therapy or progressing after chemotherapy induced regression, there is at present no standard recommended second-line treatment (66).. During the last decade, several

new treatment options have been established for second-line therapy of liver metastases of colorectal origin such as immuno-chemotherapy or several new cytostatic drug combinations (Table 3)(73-82). Nevertheless, no definite regimen has been established for second-line therapy in these patients when systemic chemotherapy has failed as first option. Several phase II trials dealing with this problem could not show any benefit in terms of response or survival. In contrast to these negative findings, some other trials from the last three years have yielded promising results using new cytostatics such as irinotecan or oxaliplatin. Data reported by Mitry et al. (1998) or Maindrault-Goebel et al. (1999) as well as Van Cutzem et al. (1999) have comprised relevant data from prospective randomized trials on effective systemic chemotherapy as second-line treatment of inoperable colorectal liver metastases showing a median survival time of around 10 months. Nevertheless, response rates were disappointing and did not exceed 25 %.

In case of involvement of the liver only a regional application of cytostatics to maximise local drug concentrations can break through tumour cell resistance. There are a few reports in the literature about an effective second –line regional chemotherapy (Table 4) (83-89). Interesting enough, reported response rates were higher ranging between 17,6 % and 48 %. This led to a positive trend in survival ranging between 7 and 24 months. In this respect a direct comparison between systemic and regional second –line therapy is difficult. Due to integration of patients with metastases at multiple organ sites there can be a possible selection bias favouring regional therapy. Nevertheless in case of liver involvement only regional chemotherapy seems to be superior to systemic chemotherapy as second line treatment.

D adjuvant therapy

Resection of liver metastases is the only possible curative approach for patients with colorectal liver metastases. Due to a high relapse rate after complete resection, especially in the liver, there is need for effective adjuvant treatments. Early studies have documented that adjuvant 5-FU-based systemic chemotherapy is not combined with a significant survival benefit (90-92).

Up to now three large randomized trials of adjuvant HAI have been reported. Lorenz et al. have published the results of a prospective randomized trial in 226 patients about resection alone versus resection plus 6 months of HAI of 5-FU/LV given as a 5-day continuous infusion every 28 days (93). Impact of HAI therapy in this study is difficult to assess because only 74% of patients assigned to HAI initiated this treatment. This study was terminated early, as an interim analysis suggested a very low chance of demonstrating any survival benefit for adjuvant therapy.

In an Intergroup study 109 patients were randomized to resection alone versus resection followed by four cycles of HAI of FUDR and infusional systemic 5-FU, followed by eight cycles of systemic 5-FU(94) Despite an advantage in disease free survival (disease-free after 4-year 46% versus 25%, $p = 0.04$) the overall survival was not significantly different (62% versus 53%, $p = 0.6$).

156 patients with resected hepatic metastases were randomized to 6 months of systemic 5-FU/LV or systemic 5-FU/LV plus HAI of FUDR/dexamethasone in another randomized trial reported by N. Kemeny et al.(95). The 2-year survival rate was 86% in the combined-therapy group versus 72% for systemic therapy alone ($p = 0.03$), with median survivals of 72.2 and 59.3 months, respectively. The 2-year hepatic

progression-free survival (HPFS) rate was 90% for combined therapy and 60% for monotherapy ($p < 0.001$).

Whereas the German study couldn't show any advantage of adjuvant HAI after liver resection the latter two studies demonstrated lower hepatic and extrahepatic rates of recurrence. The 2-year survival rate after liver resection (86%) was significantly better with the combined therapy compared with adjuvant systemic therapy alone (72%) . The difference between these trials not only was the drug (FUDR vs. 5-FU), but also the mode and intensity of medication; both factors will have influenced the results and outcome.

Conclusions

A great deal of progress has been made since introduction of regional chemotherapy in the treatment of colorectal liver metastases around four decades ago. Due to improvement in surgical techniques and development of new catheters and pump systems complication rates of HAI could be decreased throughout the last years. Actually HAI is a safe procedure with a high efficacy in front line therapy of colorectal liver metastases as documented by many prospective randomized trials. Actually many studies are under way to improve local efficacy by integrating newer drugs as Oxaliplatin and Irinotecan into HAI treatments.

Patients with primarily unresectable tumour formations in the liver are always candidates for an neo-adjuvant approach in order to shrink the metastases to a size that resection will be possible. The use of HAI in the setting of unresectable metastatic disease confined to the liver seems to be of the most important subjects of investigation for the near future. Due to the fact that the liver is a primary site for drug metabolism, many drugs that perfuse the liver are metabolized during the first pass through it. This extraction phenomenon allows

high concentrations of several cytostatic agents to remain in the liver whilst minimizing systemic concentrations. This seems appropriate especially for chemoembolization. Introducing a vascular occlusion agent combined with cytostatic drugs into the hepatic artery results in a dual ischemic and cytotoxic insult in the tumour-infiltrated area. In addition to that, vascular occlusion results in the prolongation of transit time through the vascular bed of the tumour with increasing time of exposure of the tumour cells to the chemotherapy. Early results of this approach as an inductive therapy for unresectable liver metastases are encouraging.

Hepatic arterial chemotherapy consistently yields higher response rates than does systemic therapy. This is even true in case of second line therapy for patients progressive after initially effective therapy. Today HAI therapy is a fundamental part of therapeutic armamentarium against metastases of colorectal origin defined to the liver which can be used not only as front line therapy, but also as effective inductive treatment in case of inoperable tumour formations, as second line therapy and as adjuvant treatment option after potentially curative resection.

References

1. Pisani P, Parkin DM, Ferlay J : Estimates of the worldwide mortality from eighteen major cancers in 1985 : implications for prevention and projections of future burden. *Int J Cancer* 1993;55:891-903
2. Levi F, Lucchini F, La Vecchia C, Negri E ; Trends in mortality from cancer in the European Union, 1955 – 1994 *Lancet* 1999, 354 : 742-3
3. Kune GA, Kune S, Field B et al. Survival in patients with large bowel cancer : A population based investigation from Melbourne colorectal cancer study. *Dis Colon Rectum* 1990 ; 33 (11) : 938 – 46
4. Faivre J, Rat P, Arveux P. Epidemiologie des metastases hepatiques des cancer de colon. In: Nordlinger B. Jaeck D (eds.) *Traitments des metastases hepatiques des cancers colorectaux*, Paris Springer Verlag; 1992 : 2 –9
5. Cohen MC, Minsky BD, Schilsky RI. Cancer of the colon. In De vita VT, Hellman S, Rosenberg SA (eds.) *Cancer; Principles and Practice in Oncology*, 5th edition, Philadelphia, PA: JB Lippincott 1993; 1144 – 97
6. Nordlinger B, Guiguet M, Vaillant JC et al. Surgical resection of colorectal carcinoma metastases of the liver; *Cancer* 1996, 77: 1254 – 62
7. Cady B, Jenkins R, Steele GD Jr et al. Surgical margin in hepatic resection for colorectal metastases. A critical and improvable determinant of outcome. *Ann Surg* 1998; 227: 566-71
8. Fong Y, Cohen AM, Fortner JG, et al. Liver resection on colorectal metastases *JCO* 1997, 15 (3): 938-46
9. Pougier P, Milan C, Lazorthes F et al. Prospective study of prognostic factors in patients with unresected hepatic metastases from colorectal cancer: *Foundation Francaise de Cancerologie Gigestive*. *Br J Surg* 1995; 82: 1397 – 1400
10. Stangl R, Altendorf-Hofmann A, Charnley RM et al. Factors influencing the natural history of colorectal liver metastases. *Lancet* 1994; 343: 1405 – 10
11. Thirion P, Wolmark N, Haddad E, et al. Survival impact of chemotherapy in patients with colorectal metastases confined to the liver: A re-analysis of 1458 non-operable patients randomised in 22 trials and 4 meta-analyses *Ann Oncol* 1999; 10: 1317-20
12. Advanced Colorectal Cancer Meta-Analyses Project. Modulation of 5-fluorouracil by leucovorin in patients with advanced colorectal cancer: Evidence in terms of response rate. *J Clin Oncol*. 1992; 10: 896-903
13. Advanced Colorectal Cancer Meta-Analyses Project. Meta-analyses of randomised trials testing biochemical modulation of 5-fluorouracil by Methotrexat in metastatic colorectal cancer *J Clin Oncol* 1994; 12: 960 –969
14. Meta-Analysis Group in Cancer. Efficacy of intravenous continuous infusion of 5-fluorouracil compared with bolus administration in advanced colorectal cancer *J Clin Oncol* 1998; 16: 301-8
15. de Gramont A, Bosset JF, Milan C et al. Randomized trial comparing monthly low-dose leucovorin and fluorouracil bolus with bimonthly high-dose leucovorin

- and fluorouracil bolus plus continuous infusion for advanced colorectal cancer: a French intergroup study. *J Clin Oncol* 1997;15:808–815
16. Mitry, E., Ducreux, M., and Rougier, P. Second-line irinotecan chemotherapy in the treatment of metastatic colorectal cancers: phase III trials. *Bull Cancer*. 1998 Dec; Spec No: 38-42.
 17. Van Cutsem, E. and Blijham, G. H. Irinotecan versus infusional 5-fluorouracil: a phase III study in metastatic colorectal cancer following failure on first-line 5-fluorouracil. V302 Study Group. *Semin Oncol*. 1999 Feb; 26(1 Suppl 5): 13-20.
 18. Maindrault-Goebel, F.; Louvet, C.; Andre, T.; Carola, E.; Lotz, J. P.; Molitor, J. L.; Garcia, M. L.; Gilles-Amar, V.; Izrael, V.; Krulik, M., and de Gramont, A. Oxaliplatin added to the simplified bimonthly leucovorin and 5- fluorouracil regimen as second-line therapy for metastatic colorectal cancer (FOLFOX6). GERCOR. *Eur J Cancer*. 1999 Sep; 35(9):1338-42
 19. Douillard JY, Cunningham D, Roth AD et al. Irinotecan combined with fluorouracil compared with fluorouracil alone as first-line treatment for metastatic colorectal cancer: a multicentre randomised trial. *Lancet* 2000;355:1041–1047.
 20. Saltz LB, Cox JV, Blanke C et al. Irinotecan plus fluorouracil and leucovorin for metastatic colorectal cancer. Irinotecan Study Group. *N Engl J Med* 2000;343:905–914.
 21. de Gramont A, Figer A, Seymour M et al. Leucovorin and fluorouracil with or without oxaliplatin as first-line treatment in advanced colorectal cancer. *J Clin Oncol* 2000;18:2938–2947.
 22. Sullivan RD, Norcross JW, Watkins E Jr. Chemotherapy of metastatic liver cancer by prolonged hepatic-artery infusion. *N Engl J Med* 1964;270:321–327.
 23. Breedis C, Young C. The blood supply of neoplasms in the liver. *Am J Pathol* 1954;30:969–985.
 24. Ackerman NB. The blood supply of experimental liver metastases. IV. Changes in vascularity with increasing tumour growth. *Surgery* 1974; 75: 589-96
 25. Ensminger WD, Gyves JW. Clinical pharmacology of hepatic arterial chemotherapy. *Semin Oncol* 1983;10:176–182.
 26. Ensminger WD: Intraarterial Therapy, in Perry MC (ed): *The Chemotherapy Source Book*. Baltimore, MD, Williams and Wilkins, 1992, pp 256-271
 27. Collins JM. Pharmacologic rationale for regional drug delivery. *J Clin Oncol* 1984;2(5):498-504
 28. Pelosi E, Bar F, Battista S, Bello et al.. Hepatic arterial infusion chemotherapy for unresectable confined liver metastases: prediction of systemic toxicity with the application of a scintigraphic and pharmacokinetic approach. *Cancer Chemother Pharmacol* 1999; 44: 505-510
 29. Kar R, Cohen RA, Terem TM et al. Pharmacokinetics of 5-fluorouracil in rabbits in experimental regional chemotherapy *Cancer Res* 1986;46:4491-5
 30. Schalhorn A in Boese-Landgraf J, Gallkowski U, Layer G, Schalhorn A (Hrsg.) :*Regionale Tumorthapie : Allgemeine Pharmakologie* , Springer-Verlag 2003, 5-10

31. Takeshita T, Iwasaki M, Narita M et al. Blood and tumor levels of tegafur, 5-fluorouracil and uracil *Gan To Kagaku Ryoho* 1988;15:3053-8
32. Ensminger WD. Intrahepatic arterial infusion of chemotherapy: pharmacologic principles. *Semin Oncol* 2002;29:119–125.
33. Wickremesekera JK, Cannan RJ, Stubbs RS. Hepatic artery access ports: recognizing and avoiding the problems. *Aust N Z J Surg* 2000;70:496–502
34. Yasuda S, Noto T, Ikeda M et al. Hepatic arterial infusion chemotherapy using implantable reservoir in colorectal liver metastasis. *Gan To Kagaku Ryoho* 1990;17:1815–1819
35. Heinrich S, Petrowsky H, Schwinnen I et al. Technical complications of continuous intra-arterial chemotherapy with 5-fluorodeoxyuridine and 5-fluorouracil for colorectal liver metastases. *Surgery* 2003;133:40–48.
36. Curley SA, Chase JL, Roh MS et al. Technical considerations and complications associated with the placement of 180 implantable hepatic arterial infusion devices. *Surgery* 1993;114:928–935
37. Huang XQ, Huang ZQ, Duan WD, et al.. Severe biliary complications after hepatic artery embolization. *World J Gastroenterol* 2002; 8: 119-123
38. Abramson RG, Rosen MP, Perry LJ, et al.. Cost-effectiveness of hepatic arterial chemoembolization for colorectal liver metastases refractory to systemic chemotherapy. *Radiology* 2000; 216: 485-491
39. Popov I, Lavrnic S, Jelic S, et al. Chemoembolization for liver metastases from colorectal carcinoma: risk or a benefit. *Neoplasma* 2002; 49: 43-48
40. Cohen AD, Kemeny NE An update on hepatic arterial infusion chemotherapy for colorectal cancer. *The Oncologist* 2003;8:553-566
41. Grage TB, Vassilopoulos PP, Shingleton WW et al. Results of a prospective randomized study of hepatic artery infusion with 5-fluorouracil versus intravenous 5-fluorouracil in patients with hepatic metastases from colorectal cancer: A Central Oncology Group study. *Surgery*. 1979 Oct;86(4):550-5.
42. Kemeny N, Daly J, Reichman B, Geller N, Botet J, Oderman P. Intrahepatic or systemic infusion of fluorodeoxyuridine in patients with liver metastases from colorectal carcinoma – A randomized trial. *Ann Intern Med* 1987; 107; 459 – 65
43. Chang AE, Schneider PD, Sugarbaker PH et al. A prospective randomized trial of regional versus systemic continuous 5-fluorodeoxyuridine chemotherapy in the treatment of colorectal liver metastases *Ann Surg* 1987; 206; 985 –93
44. Hohn DC, Stagg RJ, Freidman MA et al. A randomized trial of continuous intravenous versus hepatic intraarterial floxuridine in patients with colorectal cancer metastatic to the liver: the Northern California Oncology Group Trial *J Clin Oncol* 1989; 7; 1646-54
45. Wagman LD, Kemeny MM, Leong L et al. A prospective, randomized evaluation of the treatment of colorectal cancer metastatic to the liver. *J Clin Oncol* 1990;8:1885–1893.
46. Martin JK, O’Connell MJ, Wiegand HS et al. Intra-arterial floxuridine vs. systemic fluorouracil for hepatic metastases from colorectal cancer. A randomized trial *Arch Surg* 1990; 125; 1022-7

47. Rougier P, Laplanche A, Huguier M et al. Hepatic arterial infusion of floxuridine in patients with liver metastases from colorectal carcinoma: long-term results of a prospective randomized trial. *J Clin Oncol* 1992; 10; 1112-18
48. Allen-Mersh TG, Earlam S, Fordy C et al. Quality of life and survival with continuous hepatic-artery floxuridine infusion for colorectal liver metastases. *Lancet* 1994;344:1255–1260. 41.
49. Lorenz M, Muller HH. Randomized, multicenter trial of fluorouracil plus leucovorin administered either via hepatic arterial or intravenous infusion versus fluorodeoxyuridine administered via hepatic arterial infusion in patients with nonresectable liver metastases from colorectal carcinoma. *J Clin Oncol* 2000;18:243–254
50. Kerr DJ, McArdle CS, Ledermann J et al. Intrahepatic arterial versus intravenous fluorouracil and folinic acid for colorectal cancer liver metastases: a multicentre randomised trial. *Lancet* 2003;361:368–373.
51. Kemeny N, Conti JA, Cohen A et al. Phase II study of hepatic arterial floxuridine, leucovorin, and dexamethasone for unresectable liver metastases from colorectal carcinoma. *J Clin Oncol* 1994;12:2288–2295
52. Meta-Analysis Group in Cancer. Reappraisal of hepatic arterial infusion in the treatment of nonresectable liver metastases from colorectal cancer. *J Natl Cancer Inst* 1996;88:252–258
53. Harmantas A, Rotstein LE, Langer B. Regional versus systemic chemotherapy in the treatment of colorectal carcinoma metastatic to the liver. Is there a survival difference? Meta-analysis of the published literature. *Cancer* 1996;78:1639–1645
54. Kemeny N, Gonen D, Sullivan LD et al. Phase I study of hepatic arterial infusion of floxuridine and dexamethasone with systemic irinotecan for unresectable hepatic metastases from colorectal cancer. *J Clin Oncol* 2001;19:2687–2695
55. Munck JN, Riggi M, Rougier P, et al.. Pharmacokinetic and pharmacodynamic advantages of pirarubicin over adriamycin after intraarterial hepatic administration in the rabbit VX2 tumor model. *Cancer Res.* 1993 Apr 1;53(7):1550-4
56. Fallik D, Ychou M, Jacob J, Colin et al. Hepatic arterial infusion using pirarubicin combined with systemic chemotherapy: a phase II study in patients with nonresectable liver metastases from colorectal cancer. *Ann Oncol.* 2003 Jun;14(6):856-63.
57. Zelek L, Bugat R, Cherqui D, Multimodal therapy with intravenous biweekly leucovorin, 5-fluorouracil and irinotecan combined with hepatic arterial infusion pirarubicin in non-resectable hepatic metastases from colorectal cancer (a European Association for Research in Oncology trial). *Ann Oncol.* 2003 Oct;14(10):1537-42.
58. Fiorentini G, Rossi S, Dentico P. Irinotecan hepatic arterial infusion chemotherapy for hepatic metastases from colorectal cancer: a phase II clinical study. *Tumori.* 2003 Jul-Aug;89(4):382-4.

59. Kern W, Beckert B, Lang N et al. Phase I and pharmacokinetic study of hepatic arterial infusion with oxaliplatin in combination with folinic acid and 5-fluorouracil in patients with hepatic metastases from colorectal cancer. *Ann Oncol* 2001;12:599–603
60. Mancuso A, Giuliani R, Accettura C, Hepatic arterial continuous infusion (HACI) of oxaliplatin in patients with unresectable liver metastases from colorectal cancer. *Anticancer Res.* 2003 Mar-Apr;23(2C):1917-22.
61. Hochster H, Chachoua A, Speyer J et al. Oxaliplatin with weekly bolus fluorouracil and low-dose leucovorin as first-line therapy for patients with colorectal cancer. *J Clin Oncol.* 2003 Jul 15;21(14):2703-7.
62. Bismuth H, Adam R, Levi F, et al. Resection of nonresectable liver metastases from colorectal cancer after neoadjuvant chemotherapy. *Ann Surg.* 1996 Oct;224(4):509-20;
63. Adam R, Huguet E, Azoulay D, Hepatic resection after down-staging of unresectable hepatic colorectal metastases. *Surg Oncol Clin N Am.* 2003 Jan;12(1):211-20
64. Rivoire M, De Cian F, Meeus P, et al. Combination of neoadjuvant chemotherapy with cryotherapy and surgical resection for the treatment of unresectable liver metastases from colorectal carcinoma. *Cancer.* 2002 Dec 1;95(11):2283-92.
65. Giacchetti S, Itzhaki M, Gruia G, et al. Long-term survival of patients with unresectable colorectal cancer liver metastases following infusional chemotherapy with 5-fluorouracil, leucovorin, oxaliplatin and surgery. *Ann Oncol.* 1999 Jun;10(6):663-9.
66. Tournigand C, Andre T, Achille E, FOLFIRI followed by FOLFOX6 or the reverse sequence in advanced colorectal cancer: a randomized GERCOR study. *J Clin Oncol.* 2004 Jan 15;22(2):229-37.
67. Muller H, Nakchbandi W, Chatzissavvidis I, Valek V. Intra-arterial infusion of 5-fluorouracil plus granulocyte-macrophage colony-stimulating factor (GM-CSF) and chemoembolization with melphalan in the treatment of disseminated colorectal liver metastases. *Eur J Surg Oncol* 2001; 27: 652-661
68. Chen MS, Li JQ, Zhang YQ, Lu et al. High-dose iodized oil transcatheter arterial chemoembolization for patients with large hepatocellular carcinoma. *World J Gastroenterol* 2002; 8: 74-78
69. Abramson RG, Rosen MP, Perry LJ, Brophy DP, Raeburn SL, Stuart KE. Cost-effectiveness of hepatic arterial chemoembolization for colorectal liver metastases refractory to systemic chemotherapy. *Radiology* 2000; 216: 485-491
70. Wallace S, Carrasco CH, Chrsagavej C, Richli WR, Wright K, Gianturco C, Hepatic artery infusion and chemoembolisation in the management of the liver. *Cardiovasc Intervent Radiol* 1990;13:153-60
71. Porta, C.; Moroni, M.; Nastasi, G.; Bobbio-Pallavicini, E., and Barazzoni, G. Utility of embolization of chemoembolization as second-line treatment in patients with advanced or recurrent colorectal carcinoma. *Cancer.* 1995 Jun 1; 75(11):2782-4.

72. Tellez C, Benson AB, Lyster MT, et al. Phase II trial of chemoembolization for the treatment of metastatic colorectal carcinoma to the liver and review of literature *Cancer* 1998; 82: 1250-59
73. Zaniboni, A.; Labianca, R.; Martignoni, G.; Barni, S.; Vinci, M.; Vaghi, M.; Pirovano, M.; Facendola, G.; Marini, G., and Luporini, G. Sequential methotrexate and 5-fluorouracil as second-line chemotherapy for advanced colorectal cancer patients pretreated with 5-fluorouracil and leucovorin: a GISCAD study. *J Chemother.* 1996 Feb; 8(1):82-4.
74. Mitry, E., Ducreux, M., and Rougier, P. Second-line irinotecan chemotherapy in the treatment of metastatic colorectal cancers: phase III trials. *Bull Cancer.* 1998 Dec; Spec No: 38-42.
75. Perez, J. E.; Lacava, J. A.; Dominguez, M. E.; et al.. Biomodulation with sequential intravenous IFN-alpha2b and 5- fluorouracil as second-line treatment in patients with advanced colorectal cancer. *J Interferon Cytokine Res.* 1998 Aug; 18(8):565-9.
76. Seitz, J. F.; Perrier, H.; Giovannini, M.; et al. 5-Fluorouracil, high-dose folinic acid and mitomycin C combination chemotherapy in previously treated patients with advanced colorectal carcinoma. *J Chemother.* 1998 Jun; 10(3):258-65.
77. Van Cutsem, E. and Blijham, G. H. Irinotecan versus infusional 5-fluorouracil: a phase III study in metastatic colorectal cancer following failure on first-line 5- fluorouracil. V302 Study Group. *Semin Oncol.* 1999 Feb; 26(1 Suppl 5): 13-20.
78. Maindrault-Goebel, F.; Louvet, C.; Andre, T; et al. Oxaliplatin added to the simplified bimonthly leucovorin and 5- fluorouracil regimen as second-line therapy for metastatic colorectal cancer (FOLFOX6). GERCOR. *Eur J Cancer.* 1999 Sep; 35(9):1338-42
79. Hartmann, J. T.; Harstrick, A.; Daikeler, T.; et al.. Phase II study of continuous 120 h infusion of mitomycin C as salvage chemotherapy in patients with progressive or rapidly recurrent colorectal cancer. *Anticancer Drugs.* 1998 Jun; 9(5):427-31.
80. Moehler M, Hoffmann T, Hildner K, et al. Weekly oxaliplatin, high-dose folinic acid and 24h-5-fluorouracil (FUFOX) as salvage therapy in metastatic colorectal cancer patients pretreated with irinotecan and folinic acid/5-fluorouracil regimens. *Z Gastroenterol.* 2002 Dec;40(12):957-64.
81. Tsavaris N, Ziras N, Kosmas C, et al. Two different schedules of irinotecan (CPT-11) in patients with advanced colorectal carcinoma relapsing after a 5-fluorouracil and leucovorin combination. A randomized study. *Cancer Chemother Pharmacol.* 2003 Dec;52(6):514-9. Epub 2003 Sep 23.
82. Sastre J, Alfonso R, Macias JA, et al. 5-fluorouracil as a protracted continuous infusion plus irinotecan (CPT-11) in patients with advanced colorectal cancer treated with fluoropyrimidine-based regimens as first line. *Anticancer Drugs.* 2003 Aug;14(7):543-7.
83. Kemeny N, Cohen A, Seiter K , Randomized trial of hepatic arterial floxuridine, mitomycin, and carmustine versus floxuridine alone in previously treated patients with liver metastases from colorectal cancer. *J Clin Oncol.* 1993 Feb;11(2):330-5.
84. Fordy C, Glover C, Davies MM, Allen-Mersh TG. Hepatic arterial floxuridine as second-line treatment for systemic fluorouracil-resistant colorectal liver metastases. *Br J Cancer.* 1998 Oct;78(8):1058-60.
85. Cyjon A, Neuman-Levin M, Rakowsky E, Liver metastases from colorectal cancer: regional intra-arterial treatment following failure of systemic chemotherapy. *Br J Cancer.* 2001 Aug 17;85(4):504-8.

86. Lavrenkov K, Man S, Mermershtain W, Cohen Y. Retrospective comparison of single-agent chemotherapy with weekly 5-fluorouracil or weekly irinotecan in previously treated patients with metastatic colorectal cancer. *J Chemother*. 2002 Feb;14(1):84-7.
87. Mancuso A, Giuliani R, Accettura C, Hepatic arterial continuous infusion (HACI) of oxaliplatin in patients with unresectable liver metastases from colorectal cancer. *Anticancer Res*. 2003 Mar-Apr;23(2C):1917-22.
88. Fiorentini G, Rossi S, Dentico P Irinotecan hepatic arterial infusion chemotherapy for hepatic metastases from colorectal cancer: a phase II clinical study. *Tumori*. 2003 Jul-Aug;89(4):382-4
89. Müller H, Nakchbandi V, Chatzisavvidis I, von Voigt C. Repetitive chemoembolization with melphalan plus intra-arterial immuno-chemotherapy within 5-fluorouracil and granulocyte-macrophage colony-stimulating factor (GM-CSF) as effective first- and second-line treatment of disseminated colorectal liver metastases. *Hepatogastroenterology*. 2003 Nov-Dec;50(54):1919-26.
90. Ruers T, Bleichrodt RP. Treatment of liver metastases, an update on the possibilities and results. *Eur J Cancer* 2002;38:1023–1033.
91. Yap B, Sheen A, Eaton D et al. A large single centre cohort of adjuvant chemotherapy following curative resection of hepatic colorectal metastases. *Proc Am Soc Clin Oncol* 2002;21:138b.
92. Portier G, Rougier P, Milan C et al. Adjuvant systemic chemotherapy (CT) using 5-fluorouracil (FU) and folinic acid (FA) after resection of liver metastases (LM) from colorectal cancer (CRC) origin. Results of an intergroup phase III study (trial FFCD-ACHBTH-AURC 9002). *Proc Am Soc Clin Oncol* 2002;21:133a.
93. Lorenz M, Muller HH, Schramm H et al. Randomized trial of surgery versus surgery followed by adjuvant hepatic arterial infusion with 5-fluorouracil and folinic acid for liver metastases of colorectal cancer. *Ann Surg* 1998;228:756–762
94. Kemeny MM, Adak S, Gray B et al. Combined-modality treatment for resectable metastatic colorectal carcinoma to the liver: surgical resection of hepatic metastases in combination with continuous infusion of chemotherapy—an intergroup study. *J Clin Oncol* 2002;20:1499–1505
95. Kemeny N, Huang Y, Cohen AM, et al: Hepatic arterial infusion of chemotherapy after resection of hepatic metastases from colorectal cancer. *N Engl J Med* 341:2039-2048, 1999

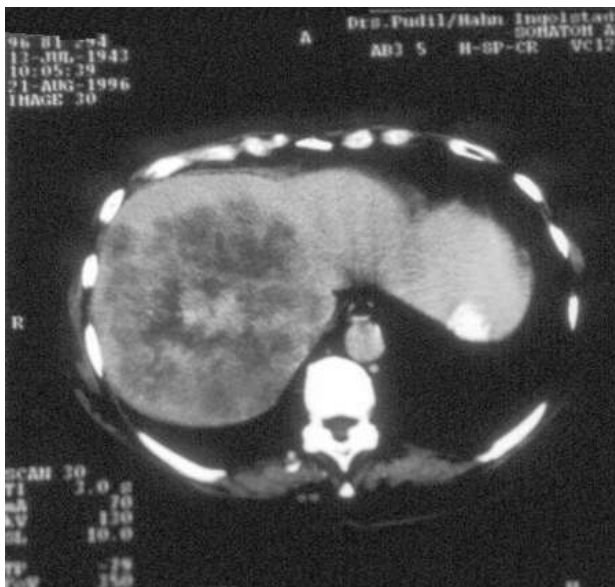Table 1 Randomized trials of HAI vs. systemic chemotherapy as frontline therapy for unresectable colorectal liver metastases

author / year	Arms	pts.	Response %	Survival months	Crossover	statistically significant
Grage 1979	ia.5-FU	31	34	13	-	ns
	iv. 5-FU	30	23	10		
Kemeny 1987	ia.FUDR	48	50	17	+	ns
	iv. FUDR	51	20	12		
Chang 1987	ia.FUDR	32	62	17	-	ns
	iv. FUDR	32	17	12		
Hohn 1989	ia.FUDR	67	42	16,5	+	ns
	iv. FUDR	76	10	15,8		
Wagman 1990	ia. FUDR	31	55	13,8	+	ns
	iv. 5-FU	10	20	11,6		
Martin 1990	ia. FUDR	39	48	12,6	-	ns
	iv. 5-FU/ LV	35	12	10,5		
Rougier 1992	ia. FUDR	81	44	15	-	0.02
	iv. 5-FU or BSC	82	9	11		
Allen-Mersh 1994	ia. FUDR	51	-	13,5	-	0.05
	iv. 5-FU or BSC	49	-	7,5		
Kemeny 1994	ia. FUDR	68	48	22,7	-	0.027
	iv. 5-FU/ LV	67	25	19,8		
Lorenz 2000	ia. FUDR	54	43	12,7	+	ns
	ia. 5-FU/ LV	57	45	18,7		
	iv. 5-FU/ LV	57	20	17,6		
Kerr 2003	ia. 5-FU/ LV	145	22	14,7	-	ns
	iv. 5-FU/ LV	145	19	14,8		

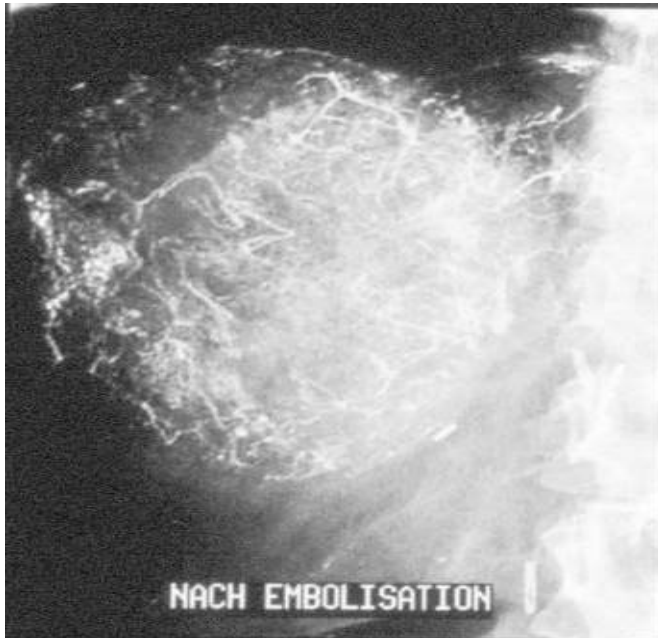
Table 2 : studies about new agents for HAI in front line treatment of colorectal liver metastases

Author	Journal	Year	pts.	Regimen	Response	Toxicity	Survivalt
Kemeny N	JCO	2001	46	FUDR, Dexa, Irinotecan	75 %	determination of MTD	not given
Kern	Ann Oncol	2001	21	ia. 5-FU, Oxaliplatin	59 %	48 %	not given
Fallik	Ann Oncol	2003	75	Pirarubicin, 5FU, LV	39.3 %	35 3 %	20.0 mon.
Fiorentini	Tumori	2003	12	ia. Irinotecan	33 %	41 %	not given
Mancuso A	Anticancer Res.	2003	17	ia. cont. 5-FU, Oxaliplatin	46 %	41 %	19.0 mon.
Zelek	Ann Oncol	2003	31	ia. Pirarubicin, iv.5-FU, Irinotecan	48 %	78 %	20.5 mon

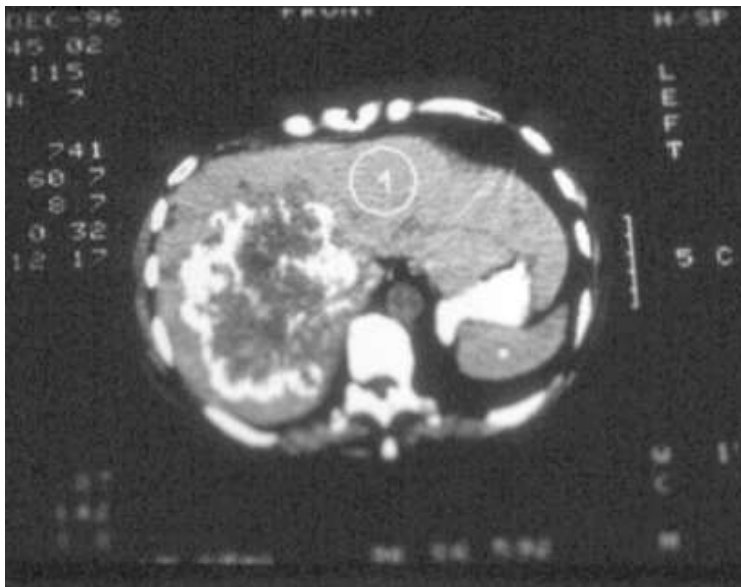
Graph 1; CT-scan of a patients with extensive involvement of the right liver lobe by colorectal metastases



Graph 2 : status after chemoembolization of hepatic artery with melphalan, Lipiodol and Gelfoam



Graph 3 : Ct-scan of the same patient after chemoembolization and shrinkage of tumour formation combined with extensive central necrosis



Graph 4 : status after extended right hemihepatectomy

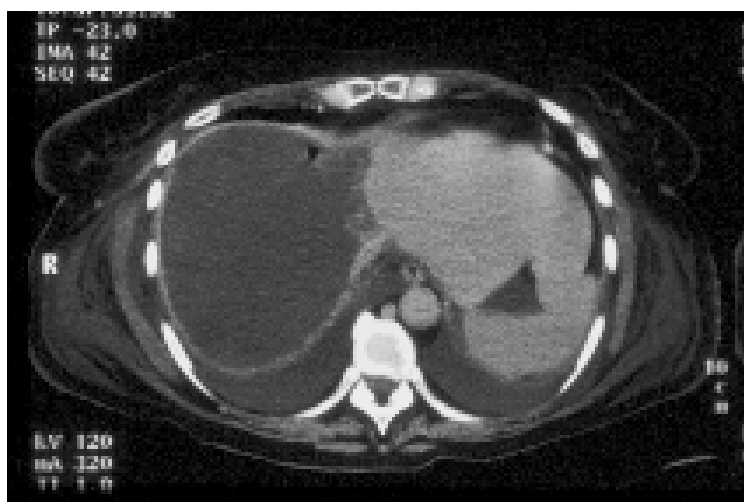


Table 3 : studies about systemic second –line chemotherapy of CRC

Author	Year	Pts	Regimen	Response	Survival
Zaniboni	1996	31	MTX, 5-FU	6.6 %	5.0
Mitry	1998	279	Irinotecan vs. BSC	-	9.2
Perez	1998	34	IFN, 5-FU	6 %	5.0
Seitz	1998	24	MMC, 5-FU	29 %	10.0
Van Cutzem	1999	267	Irinotecan vs. 5-FU	-	-
Maindrault	1999	60	Oxaliplatin, 5-FU, LV	27 %	10.8
Hartmann	1998	52	Mitomycin, 5-FU	25 %	4,7
Moehler	2002	20	cont- 5-FU, Oxaliplat	0 %	8.3
Tsavaris	2003	120	Irinotecan	24 %	7.0
Sastre	2003	25	cont. 5-FU, Irinotecan	28 %	12

Table 4 : studies about regional second –line chemotherapy of CRC

Author	Year	Pts.	Regimen	Response	Survival
Kemeny N	1993	95	FUDR, MMC, BCNU Vs. FUDR	47 % 33 %	19,1 mon 14.0 mon
Fordy	1998	35	FUDR	14 %	7.0 mon.
Cyjon A .	2001	28	5-FU, LV, CDDP	48 %	12 mon.
Lavrenkov	2002	35	5FU, Irinotecan	17,6 %	22 % 1 year
Mancuso	2003	17	Oxaliplatin	46 %	19.0 mon
Fiorentini	2003	12	Irinotecan	33 %	not given
Müller	2003	36	5FU, L-Pam chemoembol.	33.4 %	24.0 mon.